

## Complicated intra-abdominal infection caused by extended drug-resistant *Achromobacter xylosoxidans*

Sing-On Teng<sup>1</sup>, Tsong-Yih Ou<sup>1</sup>, Yu-Chia Hsieh<sup>1</sup>, Wuan-Chan Lee<sup>2</sup>,  
Yi-Chun Lin<sup>2</sup>, Wen-Sen Lee<sup>1</sup>

<sup>1</sup>Division of Infectious Disease, Department of Internal Medicine,  
Taipei Medical University, Wan Fang Hospital; and <sup>2</sup>Taipei Medical University Hospital,  
Taipei, Taiwan

Received: April 14, 2008 Revised: June 6, 2008 Accepted: August 31, 2008

*Achromobacter xylosoxidans* (formerly *Alcaligenes xylosoxidans*) is a rare but important nosocomial pathogen. Antibiotic resistance has been increasing during the past decade. *A. xylosoxidans* may be confused with *Pseudomonas* spp. but, unlike *Pseudomonas* spp., this organism has peritrichous flagella. Complicated intra-abdominal infection with *A. xylosoxidans* has rarely been reported in the literature. This report is of an immunocompetent patient with acute cholecystitis complicated by an intra-abdominal abscess after surgery. Culture of both blood and ascites yielded extended drug-resistant *A. xylosoxidans*, which was only sensitive to colistin. The clinical and laboratory characteristics of *A. xylosoxidans* are presented.

**Key words:** Abdomen; *Achromobacter denitrificans*; Colistin; Infection

### Introduction

*Achromobacter xylosoxidans* was formerly classified as a pathogen of the genus *Alcaligenes* but has been reclassified as *Achromobacter* [1]. *A. xylosoxidans* is an aerobic, motile, oxidase- and catalase-positive, non-lactose-fermenting, Gram-negative bacillus. The majority of published clinical reports of *A. xylosoxidans* have been of nosocomial infections in immunocompromised patients. The mortality rate ranges from 3% for primary bacteremia to 80% for neonatal infections [2]. This report is of an immunocompetent patient with *A. xylosoxidans* bacteremia due to complicated intra-abdominal infections. The organism was resistant to carbapenems (imipenem, meropenem), ciprofloxacin, amikacin, ceftazidime, cefotaxime, cefepime, piperacillin/tazobactam, and trimethoprim-sulfamethoxazole, and was only sensitive to colistin.

Corresponding author: Dr. Wen-Sen Lee, Taipei Medical University,  
Wan Fang Hospital, No. 111, Section 3, Hsing-Long Road, Taipei  
116, Taiwan.  
E-mail: 89425@wanfang.gov.tw

### Case Report

A 27-year-old man was admitted to a regional hospital on July 12, 2005 for management of cholelithiasis complicating acute cholecystitis. Laparoscopic cholecystectomy was performed, and bile peritonitis secondary to bile leakage was noted subsequently. Due to failure to control the bile peritonitis and sepsis, the patient was transferred to the Division of Infectious Disease, Department of Internal Medicine, Wan Fang Hospital, Taipei, Taiwan, on July 28.

The patient had severe sepsis with multiple organ dysfunction, so was admitted to the intensive care unit (ICU) immediately on arrival at the Wan Fang Hospital. He was intubated with mechanical ventilator support, and a Jackson-Pratt drain was placed, with ultrasound guidance, through the right lower quadrant of the abdominal wall for drainage.

At admission, the patient was conscious, with a body temperature of 37.5°C, heart rate of 106 beats per minute, respiration rate of 26 breaths/min, and blood pressure of 112/50 mm Hg. His white blood cell count was

$25.68 \times 10^9/L$  (reference range,  $4.5-11.0 \times 10^9/L$ ), platelet count was  $324 \times 10^9/L$  (reference range,  $150-450 \times 10^9/L$ ), hemoglobin was  $127 \text{ g/L}$  (reference range,  $140-175 \text{ g/L}$ ), and hematocrit was  $0.37$  (reference range,  $0.41-0.50$ ). Abnormal renal function and oliguria were noted; his blood urea nitrogen was  $27.85 \text{ mmol/L}$  (reference range,  $2.9-8.2 \text{ mmol/L}$ ) and creatinine was  $521.27 \mu\text{mol/L}$  (reference range,  $53-106 \mu\text{mol/L}$ ). The liver function tests showed abnormalities, including aspartate aminotransferase of  $101 \text{ U/L}$  (reference range,  $20-48 \text{ U/L}$ ), alanine aminotransferase of  $56 \text{ U/L}$  (reference range,  $10-40 \text{ U/L}$ ), total bilirubin  $91.66 \mu\text{mol/L}$  (reference range,  $5-21 \mu\text{mol/L}$ ), direct bilirubin  $53.35 \mu\text{mol/L}$  (reference range,  $<3.4 \mu\text{mol/L}$ ), and  $\gamma$ -glutamyltransferase  $120 \text{ U/L}$  (reference range,  $0-30 \text{ U/L}$ ). His amylase was  $222 \text{ U/L}$  (reference range,  $25-85 \text{ U/L}$ ) and lipase was  $122 \text{ U/L}$  (reference range,  $14-280 \text{ U/L}$ ).

Computed tomography (CT) scan of the abdomen and pelvis showed pneumoperitoneum with a small amount of ascites, dilated small bowel loops, edematous colon wall, and increased infiltration at the mesentery (Fig. 1).

After admission to the ICU, the patient suddenly developed hypovolemic shock. Hemorrhage of the middle and left hepatic arteries and hemoperitoneum was confirmed by abdominal CT scan on August 1. Transcatheter arterial embolization was used to stop the bleeding. Total parenteral nutrition was administered on the same day because of poor enteral nutrition and abdominal distention with ileus.

Intravenous (IV) flomoxef  $2.0 \text{ g}$  every  $8 \text{ h}$  and IV metronidazole  $500 \text{ mg}$  every  $6 \text{ h}$  were prescribed initially as empirical therapy for intra-abdominal infection, since there was no culture report available

from the referring hospital. As the spectrum of activity of flomoxef only partially covers intra-abdominal anaerobic pathogens, metronidazole was added as empirical therapy for intra-abdominal infection. Cultures from blood, bile from the drain, and specimens from the surgical wounds were performed. No bacteria were isolated from these cultures. The sepsis and renal function improved, and the patient was successfully weaned from mechanical ventilation on August 5, 2005. The patient began enteral feeding, and he was transferred to a general ward.

On August 15, the patient developed a fever of  $39.0^\circ\text{C}$ . Repeat abdominal CT scan showed a lobulated biloma at the subhepatic area (Fig. 2). Echo-guided pigtail drainage was performed on August 16. Bile culture contained *Enterobacter cloacae*, which was resistant to flomoxef, so IV cefoperazone/sulbactam  $2.0 \text{ g}/1.0 \text{ g}$  every  $8 \text{ h}$  was started according to the sensitivity test. The fever subsided gradually.

The patient developed a fever of  $39.2^\circ\text{C}$  on September 10. Intra-abdominal infection with uncontrolled sepsis was considered. Exploratory laparotomy with surgical drainage of the abscess at the subhepatic area was performed on September 14. The antibiotics were changed to IV flomoxef  $2.0 \text{ g}$  every  $8 \text{ h}$  and IV isepamicin  $400 \text{ mg}$  once daily after a new ascites culture yielded *Klebsiella pneumoniae*. However, repeated ascites cultures from the drain tube later yielded mixed infection of group D *Streptococcus* and *E. cloacae*. Thus, the antibiotics were switched to IV vancomycin  $500 \text{ mg}$  every  $6 \text{ h}$  and IV levofloxacin  $750 \text{ mg}$  once daily. Ascites culture from the abdominal drain tube was repeated on September 25, and *Escherichia coli* and *A. xylosoxidans* were isolated.

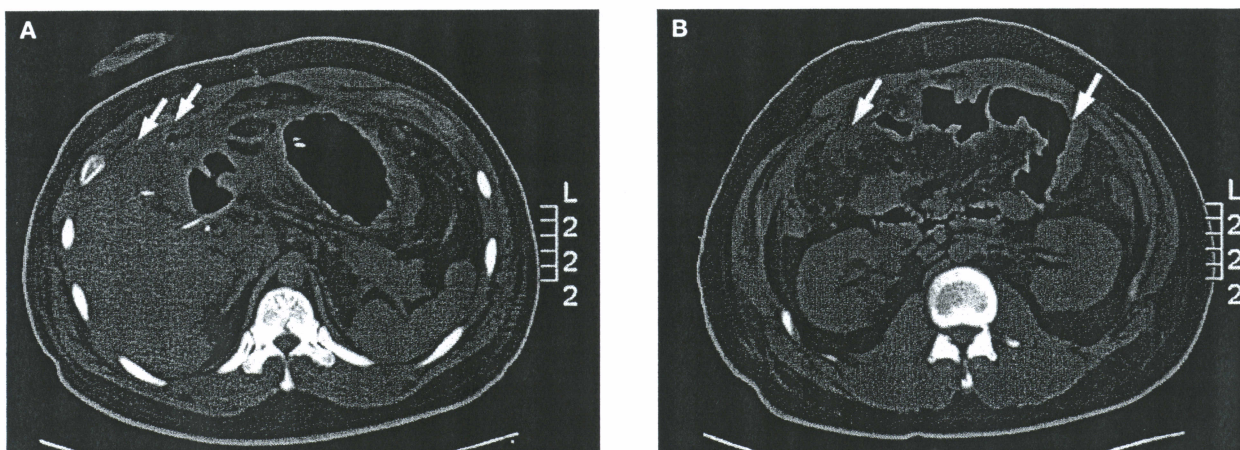


Fig. 1. Abdominal computed tomography scan showing a pneumoperitoneum (arrows) [A] and a small amount of ascites, dilated small bowel loops, edematous colon wall, and increased infiltration at the mesentery (arrows) [B].

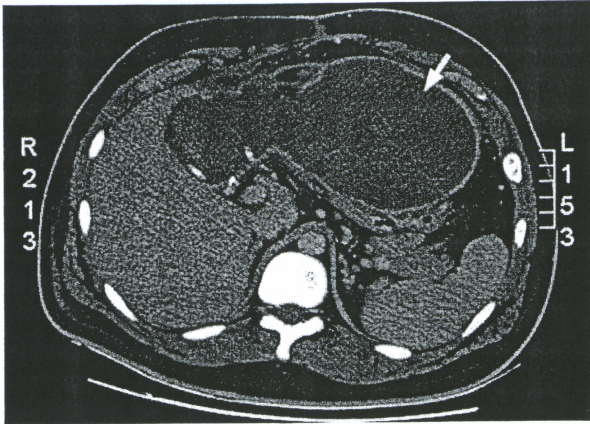


Fig. 2. Abdominal computed tomography scan showing a lobulated biloma formation (arrow) at the subhepatic area compressing on the stomach.

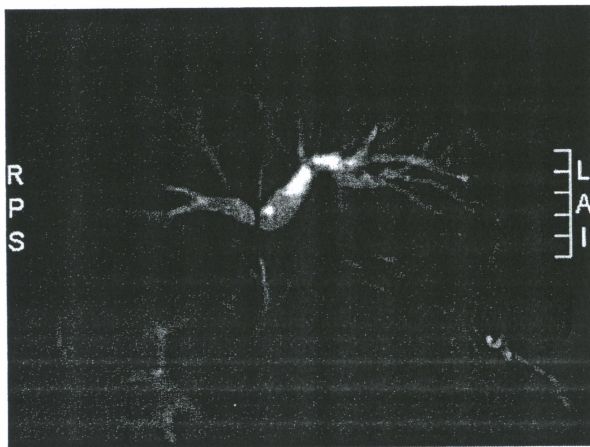


Fig. 3. Magnetic resonance cholangiopancreatography showing dilatation of the bilateral intrahepatic ducts with narrowing at the junction of the common hepatic duct and the intrahepatic ducts.

The *A. xylosoxidans* were intermediately susceptible to imipenem and ceftiofime, so the antibiotic treatment was switched to IV ceftiofime 2 g every 12 h.

Magnetic resonance cholangiopancreatography was performed on September 28, and showed granuloma formation over the common bile duct with narrowing (Fig. 3). No residual abscess or biloma were noted. The patient's family declined surgical intervention, so percutaneous transhepatic cholangiodrainage was performed on October 4 for the common bile duct obstruction. The patient's fever and clinical condition improved subsequently.

The fever developed again on October 29, and repeat ascites culture yielded *A. xylosoxidans*. Blood culture also yielded *A. xylosoxidans*. Disk diffusion test showed resistance of *A. xylosoxidans* to carbapenems

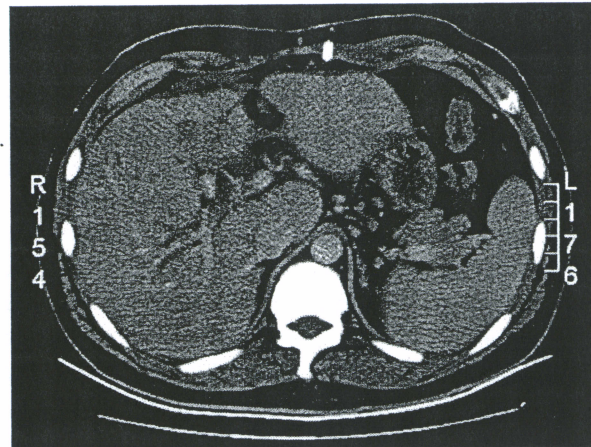


Fig. 4. Abdominal computed tomography scan after colistin therapy showing persistent dilated right intrahepatic ducts, with no evidence of the abscess in the intraperitoneal cavity.

(imipenem, meropenem), ciprofloxacin, amikacin, ceftazidime, cefotaxime, ceftiofime, piperacillin/tazobactam, and trimethoprim-sulfamethoxazole, but sensitivity to colistin, with a minimal inhibitory concentration (MIC) of 1.0 mg/L. The antibiotic treatment was therefore switched to intravenous colistin 2 MU every 6 h. However, renal function deterioration was noted 6 days later and the patient's creatinine level increased to 159.12  $\mu\text{mol/L}$ . The colistin dose was adjusted to 2 MU every 8 h and the patient's renal function recovered to within normal range after 5 days. The patient received colistin for 21 days. Repeated blood and ascites cultures showed no further growth of *A. xylosoxidans*. Follow-up abdominal CT scan after completion of colistin therapy showed persistent dilatation of the intrahepatic duct, but clear resolution of the abscess in the intraperitoneal cavity (Fig. 4).

## Discussion

*A. xylosoxidans* is found in an aqueous environment and is isolated from a wide range of clinical specimens [1,2], as it is endogenous to humans. *A. xylosoxidans* has been isolated from blood, respiratory secretions, skin, wounds, peritoneal fluid, urine, stool, cerebrospinal fluid, ear discharge, bones and joints, endocardium, and central venous catheters [2]. *A. xylosoxidans* is an opportunistic pathogen, and is the causative agent of various nosocomial infections [3]. *A. xylosoxidans* is usually involved in immunocompromised patients with infection [4]. The patient described in this report was immunocompetent, with no other comorbid disease.

*A. xylosoxidans* is a non-fermentative aerobic Gram-negative bacilli, with peritrichous motility. The organism was first described by Yabuuchi et al in 1971 [5]. The taxonomic designations for *Achromobacter* and *Alcaligenes* spp. have been confused. *Alcaligenes xylosoxidans* was transferred to the genus *Achromobacter* in 1998 [1,6]. An isolate of *A. xylosoxidans* can easily be mistaken for a non-*aeruginosa* strain of *Pseudomonas* spp. or for a strain of the *Burkholderia cepacia* complex [7].

This organism has been recovered from many medical devices and solutions in the hospital environment, as well as the water pipes of apparatus for dispensing disinfectant (didecyldimethylammonium chloride) [8]. An outbreak of long-term intravascular catheter-related bacteremia in a hemodialysis unit was caused by *A. xylosoxidans* [9]. Infected intravascular catheters have been reported to be a significant source of bacteremia [4,10].

Most infections in patients with cancer occur before or within 48 h of admission to hospital [4], but *A. xylosoxidans* was isolated 60 days after admission in this patient. *A. xylosoxidans* infections are frequently polymicrobial [4]. In this patient, *A. xylosoxidans* was accompanied by *E. coli*. As the patient had complicated intra-abdominal infections, polymicrobial infection was expected.

*A. xylosoxidans* is usually susceptible to trimethoprim-sulfamethoxazole, antipseudomonal penicillins, ceftazidime, cefoperazone,  $\beta$ -lactam/ $\beta$ -lactamase-inhibitor combinations, and carbapenems (imipenem, meropenem) [4,11]. According to the antimicrobial susceptibility pattern in Taiwan, *A. xylosoxidans* are usually susceptible in vitro to ceftazidime, piperacillin, trimethoprim-sulfamethoxazole, and imipenem, but are highly resistant to ciprofloxacin and cefepime [12,13], and resistant to aminoglycosides, ampicillin, aztreonam, cefotaxime, ceftriaxone, and other cephalosporins. It is interesting that the *A. xylosoxidans* isolated from this patient had intermediate resistance to imipenem initially, but was finally resistant to all commercially available antibiotics, except for colistin, with an MIC of 1.0 mg/L. The cause of drug resistance may have been prolonged unresolved intra-abdominal infection and long-term antibiotic therapy.

Although the infection improved initially with antibiotic treatment, a lobulated biloma with fever developed on August 15. As the patient's family declined surgical intervention, treatment was with pigtail drainage and antibiotics only. Eventually, an exploratory

laparotomy was done on September 14 for uncontrolled sepsis. Early laparotomy may have shortened the duration of antibiotic use for this patient, which is believed to prevent the development of multidrug-resistant bacteria.

Colistin, a polymyxin antibiotic discovered more than 50 years ago, has been reappraised for clinical use against multidrug-resistant Gram-negative bacteria in recent years. Recent clinical findings have focused on the evaluation of efficacy, emerging resistance, potential toxicities, and combination therapy [14]. Nephrotoxicity and neurotoxicity are the most common toxicities associated with parenteral administration. In this patient, nephrotoxicity was noted during colistin therapy, but the renal function recovered to within the normal range 5 days after adjustment of the dose from 2 MU every 6 h to every 8 h.

Multidrug-resistant pathogens are an increasing cause of nosocomial infections. Multidrug-resistant *Pseudomonas aeruginosa* and *Acinetobacter baumannii* have been emerging pathogens in the ICU. This report of multidrug-resistant *A. xylosoxidans* infection causing complicated peritonitis with bacteremia is the first to be described in the literature. Adequate surgical debridement and effective antibiotic therapy were needed to treat complicated intra-abdominal abscess. Colistin was an alternative choice for treatment of multidrug-resistant *A. xylosoxidans*. Antibiotic combination therapy is often prescribed for multidrug-resistant bacteria. However, as colistin was the only susceptible drug and there is a lack of experience of using combination therapy for *A. xylosoxidans* infection, this patient received colistin monotherapy to combat the multidrug-resistant *A. xylosoxidans* infection.

## References

1. Yabuuchi E, Kawamura Y, Kosako Y, Ezaki T. Emendation of genus *Achromobacter* and *Achromobacter xylosoxidans* (Yabuuchi and Yano) and proposal of *Achromobacter ruhlmannii* (Packer and Vishniac) comb. nov., *Achromobacter piechaudii* (Kiredjian et al.) comb. nov., and *Achromobacter xylosoxidans* subsp. *denitrificans* (Ruger and Tan) comb. nov. *Microbiol Immunol.* 1998;42:429-38.
2. Weitkamp JH, Tang YW, Haas DW, Midha NK, Crowe JE Jr. Recurrent *Achromobacter xylosoxidans* bacteremia associated with persistent lymph node infection in a patient with hyper-immunoglobulin M syndrome. *Clin Infect Dis.* 2000; 31:1183-7.
3. Cheron M, Abachin E, Guerot E, El-Bez M, Simonet M. Investigation of hospital-acquired infections due to

- Alcaligenes denitrificans* subsp. *xylosoxidans* by DNA restriction fragment length polymorphism. *J Clin Microbiol*. 1994;32:1023-6.
4. Aisenberg G, Rolston KV, Safdar A. Bacteremia caused by *Achromobacter* and *Alcaligenes* species in 46 patients with cancer (1989-2003). *Cancer*. 2004;101:2134-40.
  5. Yabuuchi E, Yano I, Goto S, Tanimura E, Ito T, Ohyama A. Description of *Achromobacter xylosoxidans* (1971). *Int J Syst Bacteriol*. 1974;24:470-7.
  6. Clermont D, Harmant C, Bizet C. Identification of strains of *Alcaligenes* and *Agrobacterium* by a polyphasic approach. *J Clin Microbiol*. 2001;39:3104-9.
  7. Steinberg JP, Rio CD. Other Gram-negative and Gram-variable bacilli. In: Mandell GL, Bennett JE, Dolin R, eds. *Principles and practice of infectious diseases*. 6th ed. Philadelphia: Churchill Livingstone; 2005:2757-8.
  8. Siebor E, Llanes C, Lafon I, Ogier-Desserrey A, Duez JM, Pechinot A, et al. Presumed pseudobacteremia outbreak resulting from contamination of proportional disinfectant dispenser. *Eur J Clin Microbiol Infect Dis*. 2007;26:195-8.
  9. Tena D, Carranza R, Barberá JR, Valdezate S. Outbreak of long-term intravascular catheter-related bacteremia due to *Achromobacter xylosoxidans* subspecies *xylosoxidans* in a hemodialysis unit. *Eur J Clin Microbiol Infect Dis*. 2005;24:727-32.
  10. Gómez-Cerezo J, Suárez I, Ríos JJ, Peña P, García de Miguel MJ, de José M, et al. *Achromobacter xylosoxidans* bacteremia: a 10-year analysis of 54 cases. *Eur J Clin Microbiol Infect Dis*. 2003;22:360-3.
  11. Duggan JM, Goldstein SJ, Chenoweth CE, Kauffman CA, Bradley SF. *Achromobacter xylosoxidans* bacteremia: report of four cases and review of the literature. *Clin Infect Dis*. 1996;23:569-76.
  12. Tsay RW, Lin LC, Chiou CS, Liao JC, Chen CH, Liu CE, et al. *Alcaligenes xylosoxidans* bacteremia: clinical features and microbiological characteristics of isolates. *J Microbiol Immunol Infect*. 2005;38:194-9.
  13. Shie SS, Huang CT, Leu HS. Characteristics of *Achromobacter xylosoxidans* bacteremia in northern Taiwan. *J Microbiol Immunol Infect*. 2005;38:277-82.
  14. Li J, Nation RL, Turnidge JD, Milne RW, Coulthard K, Rayner CR, et al. Colistin: the re-emerging antibiotic for multidrug-resistant Gram-negative bacterial infections. *Lancet Infect Dis*. 2006;6:589-601.